



# Integrated Medical Cannabis Treatment (IMCT)

การรักษาผู้ป่วยทางการแพทย์แบบบูรณาการ

## Patient Testimonial

**Dr. CHINTANA Bounthalusay**

MD., DAP&E., MPH, Medical Cannabis Doctor



## Medical Wellness Advisor



**Dr. Chintana Bounthalusay**

M.D.; DAP&E; MPH

Medical Marijuana Doctor



# Academic Qualification



Year	Qualification	University
1993	Bachelor of Medical Doctor (M.D.)	University of Science Health Vientiane Capital, Lao PDR
2003	Diploma Applied Parasitology & Entomology (DAP&E)	Institute Medical Research (IMR) Kuala Lumpur, MALAYSIA
2014	Master of Administration on Public Health (MPH)	University of Health Service Vientiane Capital, Lao PDR
2019	Cannabinoid Medicines Cannabis Drugs for Patient Treatment Modern Medicine – Thai Medicine for Professional	Mahidol University and Thai Medical Cannabis Institute, THAILAND
2020	Cannabinoid Medicines Production of Specific Cannabis Medicines: Sanan Tripop and Soil Preparation for Medical Cannabis Cultivation based on Specific Wisdom	Rajamangala University of Technology Isan Maha Sarakham and Thai Medical Cannabis Institute, THAILAND

# Experience



Year	Position	Organization
1994-1995	Head of Out Patient Department	Sing District Hospital, Luang Namtha Province, Lao PDR
1995-2000	Head of OPD, Pediatric, Obstetrics & Gynecology Dept.	Luang Namtha Province Hospital, Lao PDR
2001-2010	Deputy of Head Malaria Station	Luang Namtha Province, Lao PDR
2010-2020	Deputy Head of Hygiene Promotion	Health Care Unit, Department of Public Health, Luang Namtha Province
2020 to Present	Managing Director Medical Cannabis Advisor  Medical Wellness Advisor	LMHG, Lao PDR LMHG, Lao PDR, MHG, PAC Network Malaysia CANNA LIFE, Thailand
Others Experience	Corporation as Coordinator	NGO WB. Global fund, WHO, UNICEFF, KOICA, Malaria, Primary Health Care, Nutrition Project in the Province.



# Integrated Medical Cannabis Treatment ®

การรักษาด้วยกัญชาทางการแพทย์แบบบูรณาการ

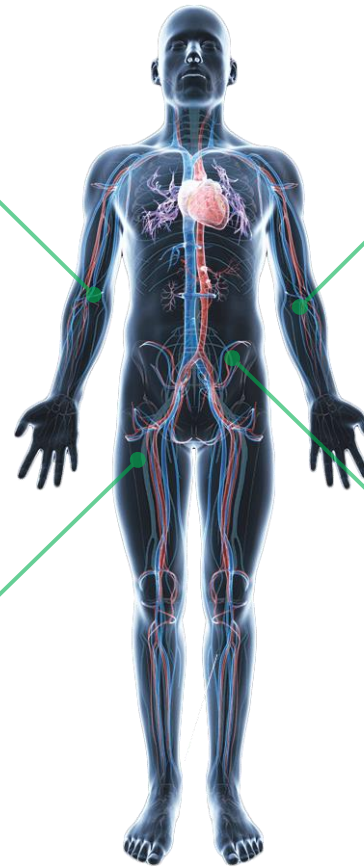
## Dr. CHIN's Methodology

วิธีการรักษาด้วยกัญชาทางการแพทย์แบบดร.จิ้น



### 1. Medical Cannabis

ใช้ CBD THC CBG CBN  
หลายรูปแบบ เช่น น้ำมัน แคปซูล ..  
ควบคุมการแพร่กระจายของมะเร็ง  
ลดขนาดของก้อนเนื้องอกได้



### 2. Medical Advance

วินิจฉัยผลแลป biopsy, TC scan,  
Tumor marker, Blood test ..  
ใช้ยาบางชนิดร่วมกัน เช่น ยาฆ่าเชื้อ ..  
เป็นเครื่องมือติดตามผลการรักษา



### 3. Herbal Advance

สมุนไพрсกัด  
ใช้เพื่อเสริมฤทธิ์การใช้กัญชา  
ฟื้นฟูบำรุงร่างกาย




### 4. Dietotherapy

โภชนบำบัด  
เพิ่มพลังงานแก่ร่างกาย  
ช่วยให้ระบบย่อยอาหารดีขึ้น

# Evidence-Based



## Patient's medical report :

**Patient Name :**   
**Ward / Clinic :** CLINIC  
**Age :** 60Y  
**IC No. :** 590602-05-5352  
**Sex :** Female  
**MRN :** 126099  
**Lab No. :** 2020990643  
**Date Received :** 06/01/2020  
**Date Reported :** 08/01/2020  
**Report Status :** Final

### HISTOPATHOLOGY REPORT

#### SPECIMEN

Right Tonsillar Mass Biopsies

#### GROSS DESCRIPTION

Specimen of pale tonsillar tissue received in three pieces, in total aggregates measuring 5mm in diameter. Cut surface shows haemorrhagic and fleshy areas. Representative sections submitted in a single block.

#### MICROSCOPIC DESCRIPTION

Multiple levels of this biopsy tissue comprises small, ulcerated, squamous epithelial mucosal tissue fragments, undermining which are identifiable stromal areas of malignant neoplasm exhibiting an organoid, epithelioid configuration of tumour islands exhibiting significantly enlarged round vesicular nuclei, conspicuous nucleoli and moderate, partially clear cytoplasm. There is no histological evidence of keratinisation, glandular formation or melanin pigment.

These tumour islands appears to arise from an adjacent, ulcerated epithelial component. The current working interpretation is of a poorly differentiated carcinoma.

#### DIAGNOSIS

**Current working interpretation:**  
**Poorly differentiated carcinoma**




#### Recommended immunohistochemical investigations:

An immunohistochemical panel comprising BerEp4, p16, p63, Synaptophysin, Chromogranin, S100 and CLA together with EBER ISH is recommended in determining the basic histogenesis of this tumour, and to exclude the differentials of a high-grade lymphoma, a mucosal and a lymphoepithelial carcinoma.

**Dr. Sri Ganesh Kalimuthu**  
 MB, BCh BAO, BmedSci, FRCPath (UK), IFCAP, FIAC  
 MMC No: 49648 NSR No: 128847  
 Consultant Pathologist

## Blood test Report



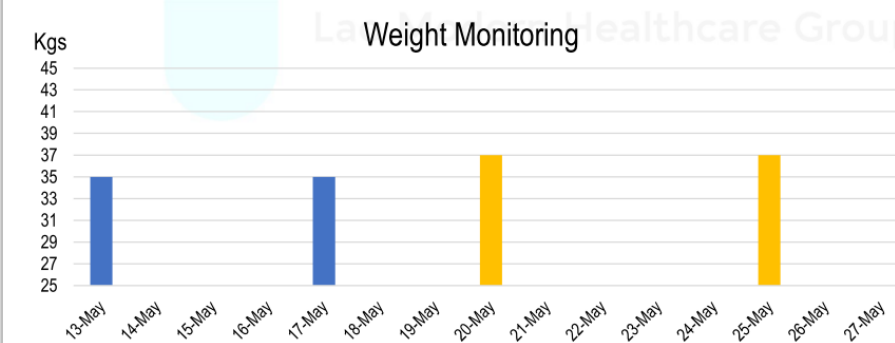
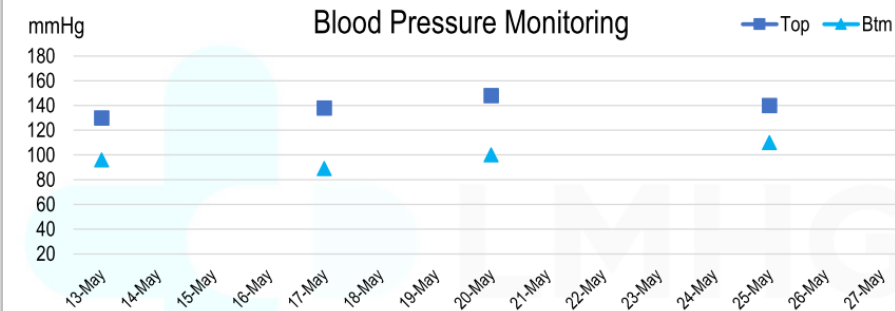
**บริษัท ล้านนาแล็บ จำกัด**  
 129/255 ถนนพหลโยธิน ตำบลป่าแดด  
 อำเภอเมือง เชียงใหม่ 50100  
 โทร. 0-5327-5131 แฟกซ์ 0-5381-2486  
**Date :** 22/01/2563  
**Lab No. :** W015  
**Name :**   
**Tel :** 083-9911623  
**Clinic :** รับบริการล้านนาแล็บ  
**HN No. :**   
**Ward :** 

TEST NAME	RESULT	UNITS	NORMAL RANGE
URINE ANALYSIS ตรวจ:			
APPEARANCE	CLEAR		Clear to Slightly cloudy
COLOR	YELLOW		Pale yellow to amber
Sp.gr	1.014		1.012-1.028
pH	7		5-6
NITRITE	NEGATIVE		NEGATIVE
ALBUMIN	NEGATIVE	mg/dl	NEGATIVE
SUGAR	NEGATIVE	mg/dl	NEGATIVE
KETONE	POSITIVE 1+		NEGATIVE
UROBILINOGEN	NEGATIVE		NEGATIVE
BILIRUBIN.	NEGATIVE		NEGATIVE
BLOOD	POSITIVE 1+		NEGATIVE
WBC	30	cell/HPF	0-5
RBC	5	cell/HPF	0-2
CAST	30	casts/LPF	0-2
BACTERIA	>200	cell/HPF	< 20
EPITHELIUM	10	cell/HPF	
OTHERS	FINE GRANULAR CAST = 10 /LPF. COARSE GRANULAR CAST < 1 /LPF. HYALINE CAST = 20 /LPF.		
HDL ไคโวลีน	43	mg/dl	>60 Negative risk factor
DIRECT LDL ไคโวลีน	108	mg/dl	<100 Optimal
CEA สารมะเร็งลำไส้	0.681	ng/ml	0-4.7

## Monitoring

From 13\_27th May 2021

Date	Body Weight (Kgs)	Blood Pressure (mmHg)	P
13 May 2021	35	130 / 96	115
17 May 2021	35	138 / 89	132
20 May 2021	37	148 / 100	119
25 May 2021	37	140 / 110	96





# Energy-up



## Dietotherapy



## Prescription

### Authority Prescription

Not valid unless authorized by the delegate

Date: 22 January 2020

#### Patient's information

Name:		Age:	61 years old		
Date of Birth:	2 June 1959	Male	<input type="checkbox"/>	Female	<input checked="" type="checkbox"/>
ID/Passport No:		weight:	65 kgs	height:	164 cm

#### Disease/Diagnosis:

Current working interpretation : Poorly differentiated carcinoma. (refer to patient's medical report)

#### Prescription/Treatment:

The patient is poorly differentiated carcinoma, which has a lump in total aggregates measuring 5 mm in diameter on the right side of the tongue. When breathing is very difficult, when sleeping there will be a blockage in the trachea and not able to eat much food.

Treatment using combination herbal medicine to treat cancer cells from the tonsils which have the following items.

1. Hemp oil 750mg + CBD 10mg 1 bottle .. 5 drops x 2 times/day
2. THC 50/50 full spectrum 5ml 1 bottle .. 2 drops x 2 times/day
3. Nano 920 water formula 900mg 1 bottle .. 1 drops 150mg x 1 times/day
4. Blue green stem cell 1 bottle .. 2 pills x 2 times/day
5. Caothong (Thai Herb) .. 1 bottle - 2 pills x 2 times/day
6. Blood purifier + water 100 ml 1 bottle .. 3 times/day
7. Liver purifier 1 bottle .. 20 drops x 3 times/day
8. Coconut oil 60 ml 1 bottle .. apply on the skin.

Due to the need for patients to consume these herbal medicines continuously which is absolutely necessary to stop the growth of cancer cells from the tonsils spread into the mouth and not to spread to the other organs as well. Therefore sufficiently prepared essential herbal medicines can be used for a period of 1 month only.

After these herbal medicines have run out, the patient still needs to receive herbal medicines continuously for 6 months, according to the below doctor's recommendations as follows:

1. Must take medication continuously and on time
2. Must control food and eat fresh vegetables and fruits as much.
3. When the medicine is about to run out, have the patient prepare to see the doctor as scheduled, according to the condition of the patient at that time.

In addition, the patient should be exercised regularly and practice the exercise of the mouth and tongue muscles every day.

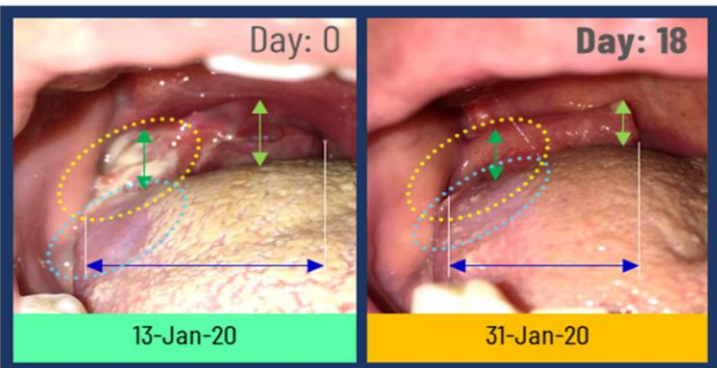
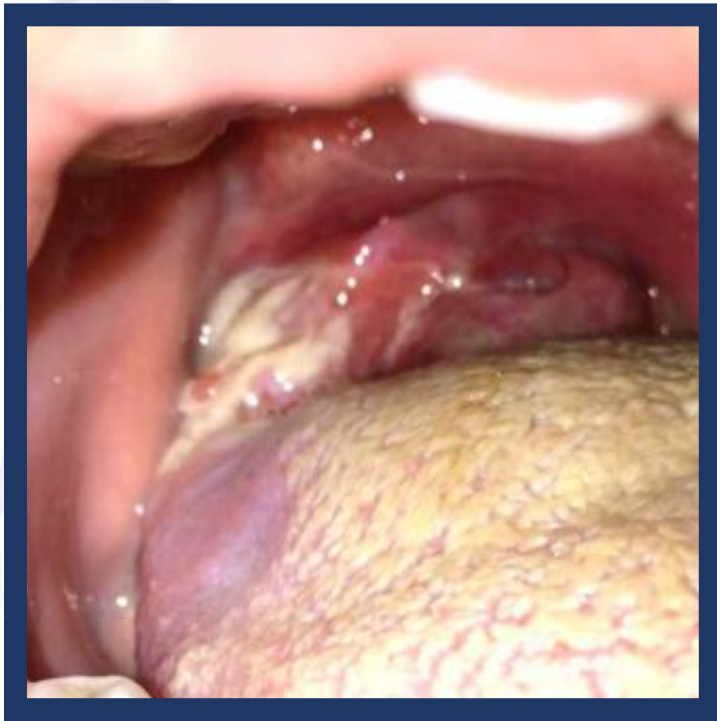Doctor in charge

Dr. Chintana Bounthalusay  
M.D; DAP&E; MPH

Attachment :

1. Medical report from Malaysia
2. Blood Test Report on Jan.13'20
3. Blood Test Report on Jan.22'20

# Lymphoma (Stage 2) (Jan.'20)

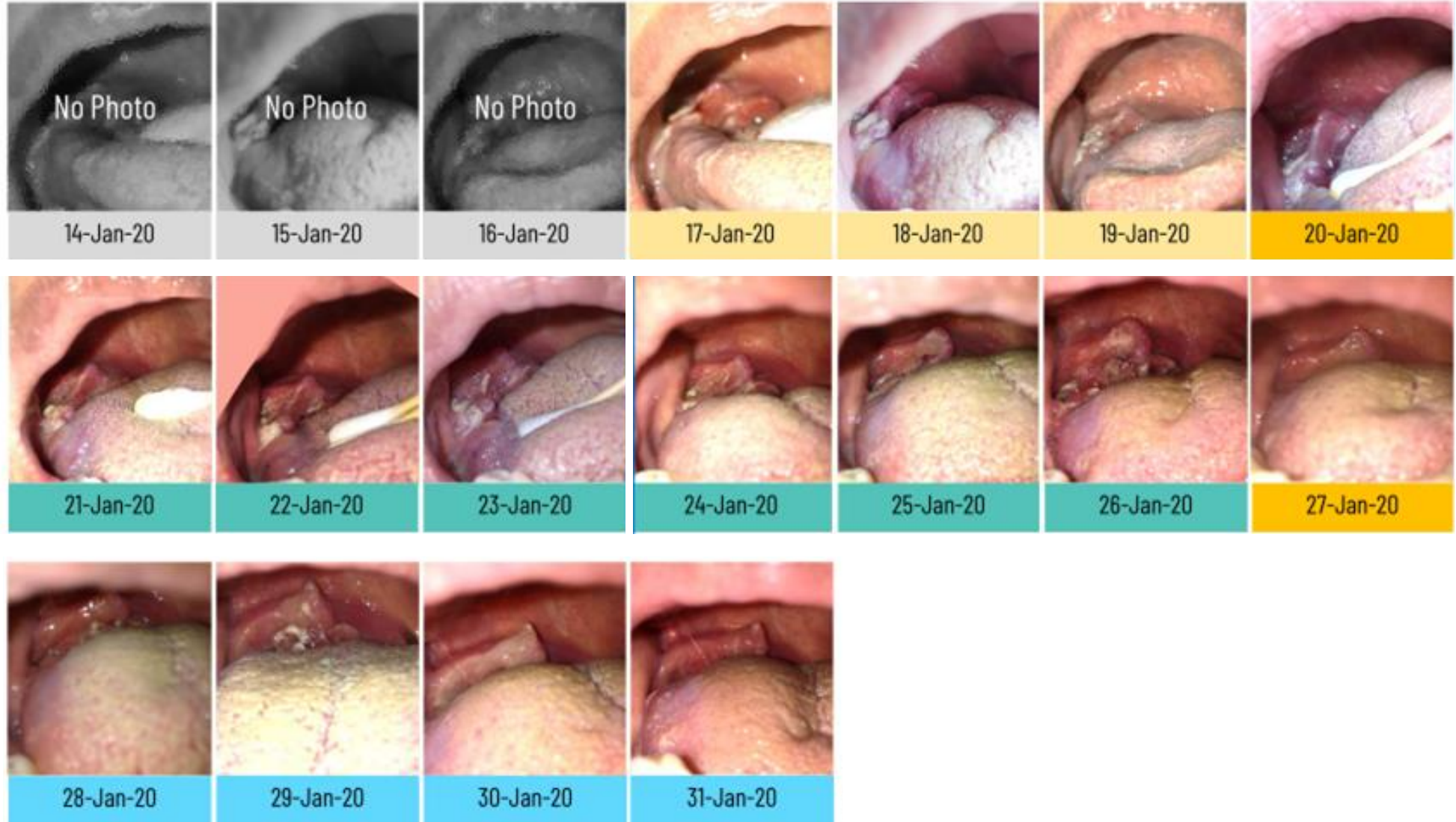
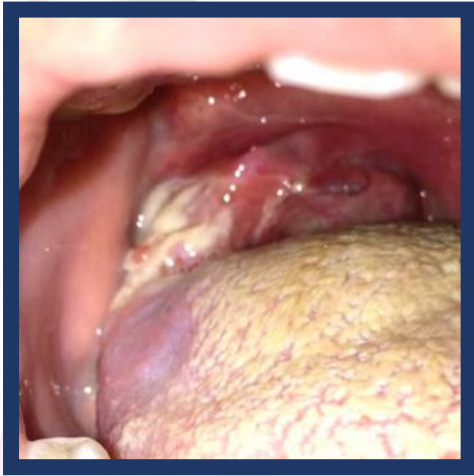


Patient:	Female, 61 years old	Nationality:	Malaysian
Disease:	High grade Non-Hodgkin's B cell lymphoma. (Stage 2)		
Symptom:	Lymph node tumor nearly covered the whole throat causing difficulty in eating and breathing.		
Treatment Prior to Using Cannabis:	She had been checked up and consulted with her doctor in Malaysia around 4 months and a doctor suggested she do chemotherapy but she refused because of scaring and looking for another alternative treatment till found medical cannabis then tried to contact us and joined our treatment together with her family which is her final decision.		
Medical Cannabis Treatment:	<ul style="list-style-type: none"> <li>- Performed blood test.</li> <li>- Check-up body physical especially tumor in the throat without fever.</li> <li>- Found bacteria on tongue, difficult for breathing, eating, and pronouncing.</li> <li>- Calculate medication doses needed.</li> <li>- Provided medical cannabis (CBD &amp; THC-based in several forms of medical cannabis) combined with herbs.</li> <li>- Provided rice porridge with mixed fruit juice everyday.</li> <li>- Daily blood pressure check, monitoring, tongue cleaning with salt water.</li> <li>- After 18 days (13-31 Jan 2020), tumor size was reduced by 30%. The patient could feel breathe and eat more and also could speak more understanding. The patient is still alive and healthy, continuing to use medical cannabis.</li> </ul>		
Patient/Relative Feedback:	The patient and her family are satisfied and happy with this alternative treatment and still use it until now.		





# Treatment with Dr. Chintana during 13-31 Jan.'20




# Bone Marrow Cancer (Stage 4) (Feb.'20)



Patient:	Male, 37 years old	Nationality:	Malaysian
Disease:	Bone Marrow Cancer (Stage 4) for 4 years		
Symptom:	Chronic pain all over body, cannot live normal life, insomnia, stress.		
Treatment Prior to Using Cannabis:	He has 183 cm in height and 43 kg in weight when he first met Dr.Chintana. Case of metastatic (spreading) nasopharyngeal carcinoma with bone and lung metastases, post-radiotherapy and chemotherapy, CT scan. Patients experience constant pain in the arms and hips and have had insomnia for 2 consecutive years.		
Medical Cannabis Treatment:	<ul style="list-style-type: none"> <li>- Performed blood test.</li> <li>- Check-up body physical.</li> <li>- Patient has a lot of pain and can't sleep, slim body and underweight.</li> <li>- Calculate medication doses needed.</li> <li>- Provided medical cannabis (CBD &amp; THC-based in several form of medical cannabis) combined with herbs.</li> <li>- Focus on energy-boosting foods with mixed fruits juice everyday.</li> <li>- Performed daily blood pressure, monitoring.</li> <li>- <b>After 1 week of medical cannabis treatment and nutrition consultation, patient felt much better and able to enjoy eating again. Patient gained 1 kg after 1 week treatment (44 kg). The patient is still alive and lives happier and still uses medical cannabis regularly.</b></li> </ul>		
Patient/Relative Feedback:	He can sleep more during the day and night, can eat more, and gain 1 kg in 1 week. In the past, when he goes to work, he feels very pain until he has been treated with medical cannabis, he feels really good and has more hopeful.		

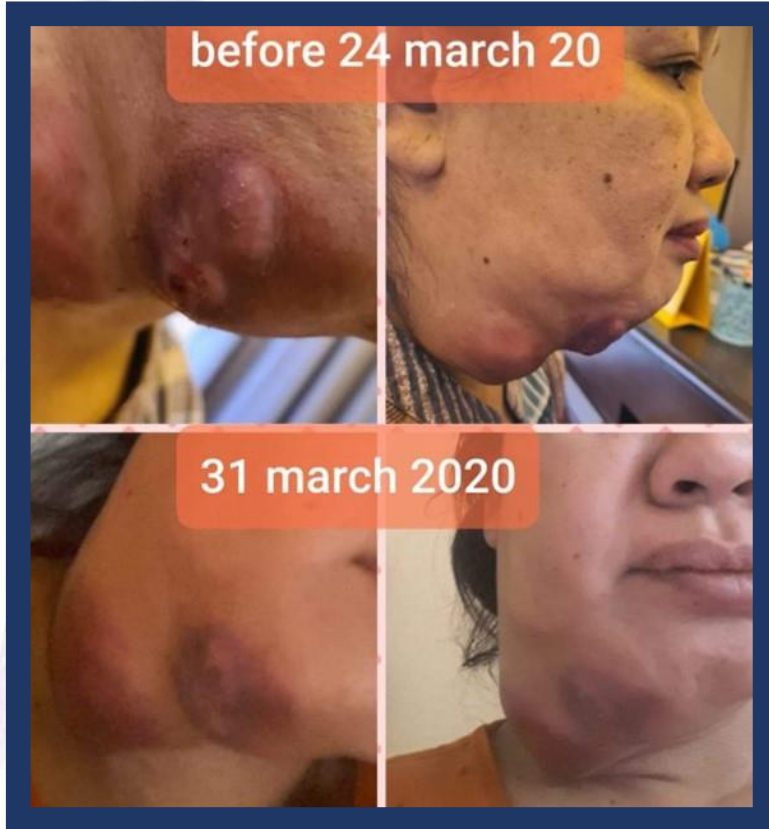

# Brain Cancer (Spreading) (Apr.'19)



Patient:	Male, 35 years old	Nationality:	Laotian
Disease:	Brain Cancer (spreading)		
Symptom:	<p>Cancer cells spread around inside the brain like rice grains.</p> <p>When he met Dr.Chin, his left eyeball almost came out due to high pressure inside the skull, tears coming out at all times, a crooked mouth that couldn't close properly with saliva coming out at all times, and chronic pain. Couldn't live his normal life.</p>		
Treatment Prior to Using Cannabis:	<p>The patient had radiation treatment in Vietnam but cancer cells that spread around inside the brain still maintain, not see any significant difference.</p>		
Medical Cannabis Treatment:	<ul style="list-style-type: none"> <li>- Check appearance condition.</li> <li>- Check blood pressure.</li> <li>- Calculate medication doses needed.</li> <li>- Provided medical cannabis (CBD &amp; THC-based in several form of medical cannabis) combined with herbs.</li> <li>- <b>After 6 months of treatment with medical cannabis, he go back to check with a doctor in Vietnam again and found that the cancer cells that spread inside the brain were almost gone which made his doctor so surprised.</b></li> </ul>		
Patient/Relative Feedback:	<p>He was delighted that the medical cannabis treatment had made him feel better, stronger, and healthy. He can work more and stay with families together with happier until now.</p>		

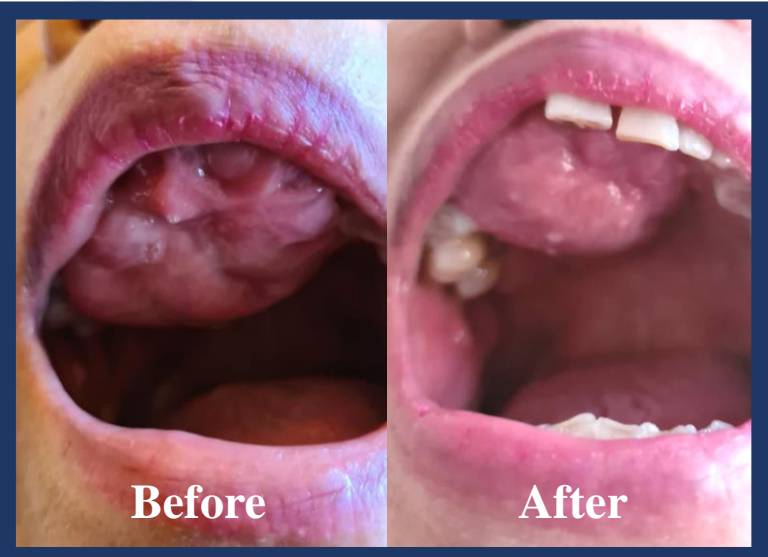# Lymphoma (Mar.'20)



Patient:	Female, 55 years old	Nationality:	Laotian
Disease:	Lymphoma		
Symptom:	big tumor, chronic pain, serious inflammation.		
Treatment Prior to Using Cannabis:	when she knew her disease, she treated it with local traditional herbs because of her poor family but it's not going better.		
Medical Cannabis Treatment:	<ul style="list-style-type: none"><li>- Check appearance condition.</li><li>- Check blood pressure.</li><li>- Calculate medication doses needed.</li><li>- Provided medical cannabis (CBD &amp; THC-based in several form of medical cannabis) combined with herbs.</li><li>- After 1 week of using medical cannabis, the tumor size decreased by 20-30%, and the inflammation also decreased.</li></ul>		
Patient/Relative Feedback:	She feels better, with less pain, and would like to continue to treat with medical cannabis.		

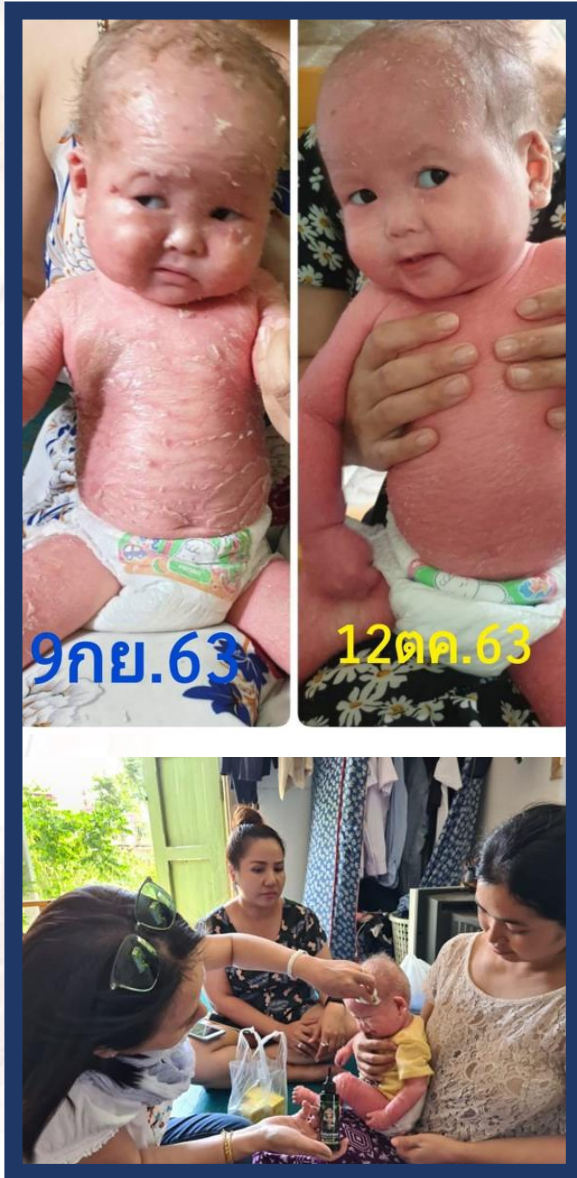

# Parotid Adenocarcinoma (Jul.'20)



Patient:	Female, 65 years old	Nationality:	Laotian
Disease:	Parotid Adenocarcinoma		
Symptom:	Cancer cells spread		
Treatment Prior to Using Cannabis:	The patient had been checked up at Thailand Cancer Center and found parotid adenocarcinoma. Her doctor advised her to do chemotherapy but she refused because of old age. So, she find another alternative treatment and started with medical cannabis.		
Medical Cannabis Treatment:	<ul style="list-style-type: none"> <li>- Check blood test and tumor maker test</li> <li>- Check appearance condition.</li> <li>- Check blood pressure.</li> <li>- Calculate medication doses needed.</li> <li>- Provided medical cannabis (CBD, THC &amp; CBG-based in several form of medical cannabis) combined with herbs.</li> <li>- <b>After using medical cannabis, cancer did not spread out and tumor size is reduced.</b></li> </ul>		
Patient/Relative Feedback:	She feels better, stronger, and healthy, and also still following instructions from doctor until now.		

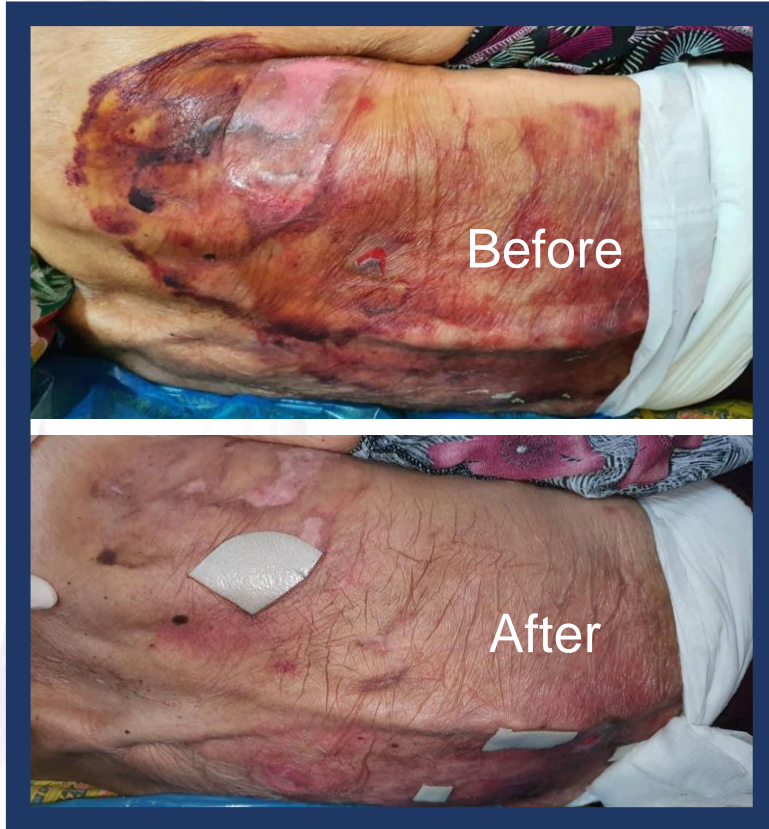# Psoriasis (Sep.'20)



Patient:	10 months baby boy	Nationality:	Laotian
Disease:	Psoriasis โรคสะเก็ดเงิน		
Symptom:	Extremely dry and cracked skin, bleeding skin, itchy all the time, suffered from pain.		
Treatment Prior to Using Cannabis:	No specific treatment. Only use baby oil lotion to keep skin hydrated.		
Medical Cannabis Treatment:	<ul style="list-style-type: none"> <li>- Drop CBD oil under tongue 30 mg. x 2 times.</li> <li>- Apply CBD oil on the skin in the morning and evening.</li> <li>- Monitoring every 2-3 months due to being far away.</li> <li>- <b>After 1 month using CBD on skin and dropping CBD with appropriate dose for baby.</b></li> </ul>		
Patient/Relative Feedback:	The mother feels thankful and happy with this treatment even though he's not fully recovering but her boy feels more comfortable after applying CBD oil.		

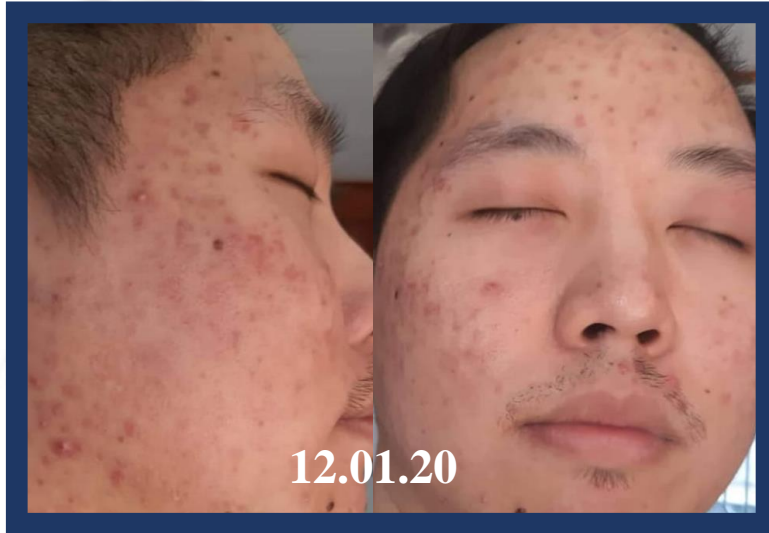

# Bedsore from Paralyzation (Jul.'21)



Patient:	Male 96 years old	Nationality:	Malaysian
Disease:	Bedsore from paralyzation for over 8 months.		
Symptom:	Poor blood circulation, sore, peeled skin etc.		
Treatment Prior to Using Cannabis:	His paralyzation, made him only lay on the bed which caused to bedsores back then to get worst.		
Medical Cannabis Treatment:	<ul style="list-style-type: none"> <li>- Check appearance condition via photos.</li> <li>- Provided medical cannabis (CBD 1,000 mg./5 ml. &amp; apply CBD on the skin morning and evening).</li> <li>- After 1 month by drop CBD and applying CBD oil on the back of the patient, 80% of bedsore back is healed.</li> </ul>		
Patient/Relative Feedback:	<p>He feels better with no pain and better sleeping.</p> <p>His bedsore back is recovered more than 80%.</p>		

# Serious Inflammatory Acne (Jan.'20)



Patient:	Male 23 years old	Nationality:	Laotian
Disease:	Serious Inflammatory Acne.		
Symptom:	Red, swollen and painful acne on the face for a long time even trying many treatments has not improved.		
Treatment Prior to Using Cannabis:	The patient spent a lot of money in various skin clinics and sometimes was treated with steroids which caused to skin problems get worst in long term.		
Medical Cannabis Treatment:	<ul style="list-style-type: none"> <li>- Check appearance condition via photos.</li> <li>- Provided medical cannabis (CBD-based in several form of medical cannabis).</li> <li>- After 2 months of Medical Cannabis treatment, can clearly see the progress of skin healing and 80-90% less inflammation and also all the acne scars are also gone and no more inflammation until today.</li> </ul>		
Patient/Relative Feedback:	He was delighted that the inflamed acne on his face had healed with CBD after several treatments but none of them improved.		



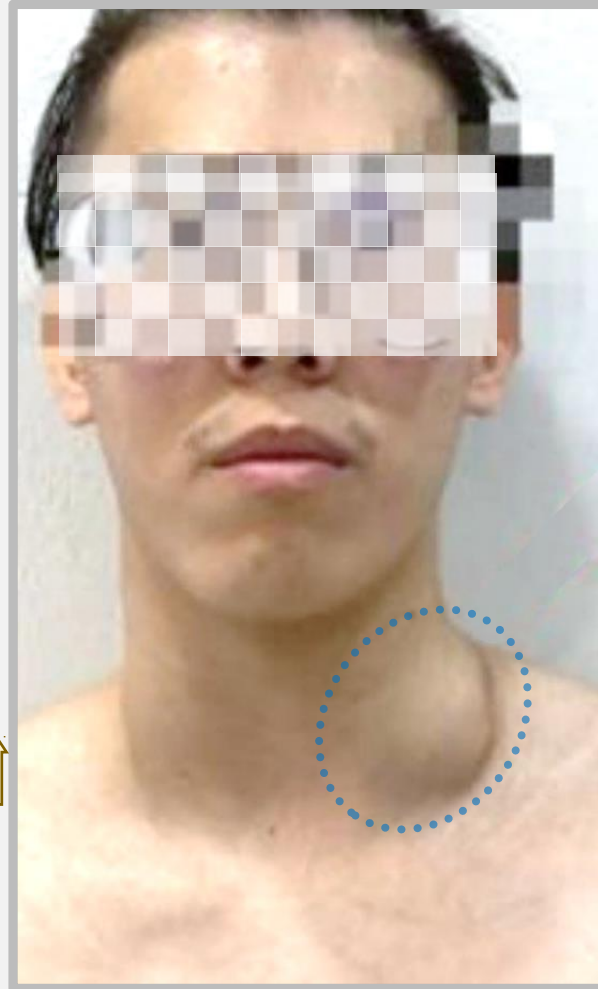# Lymphoma Treatment Progress Comparison



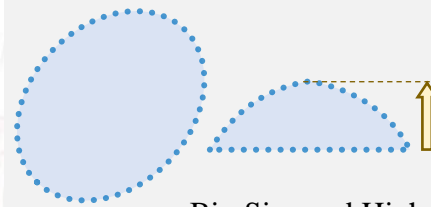## Year 2020

### Patient's Feeling:

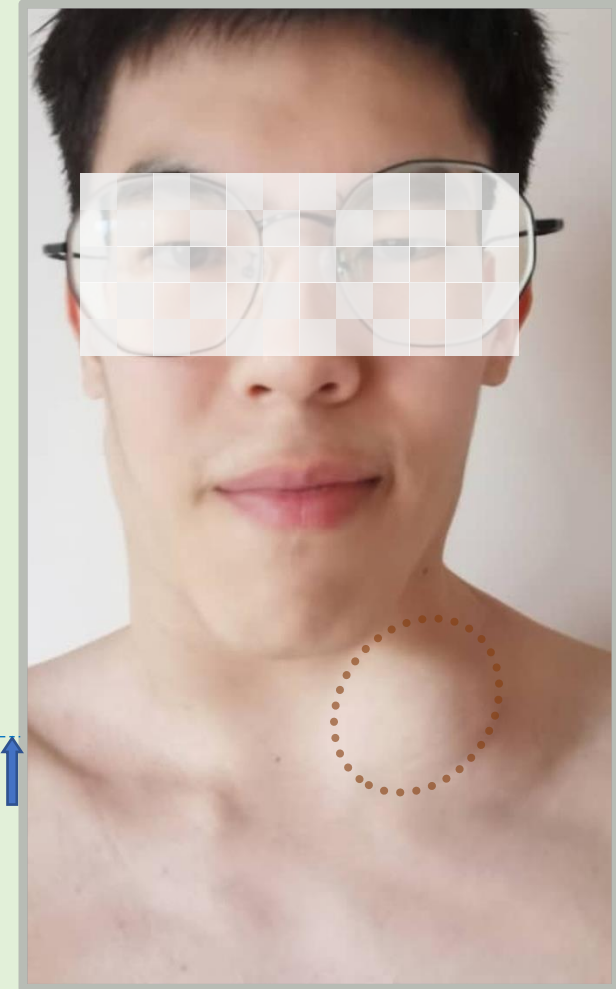
- Painful quite often
- Not comfortable
- Very much stress
- Hard to sleep
- Unable to turn his neck



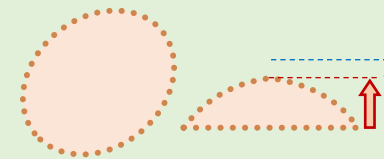
Year 2020



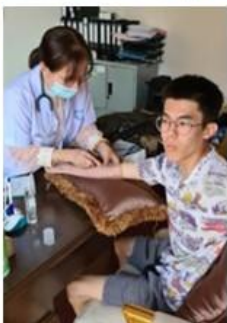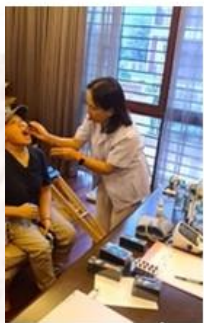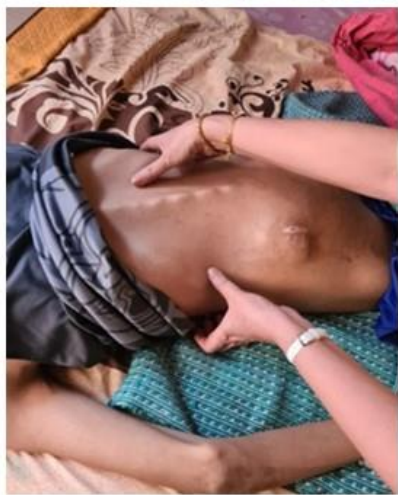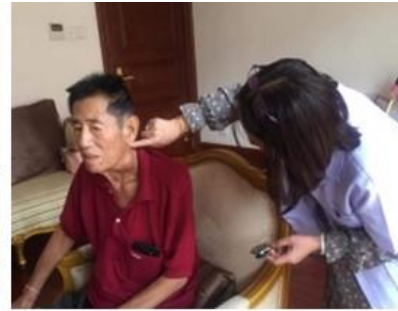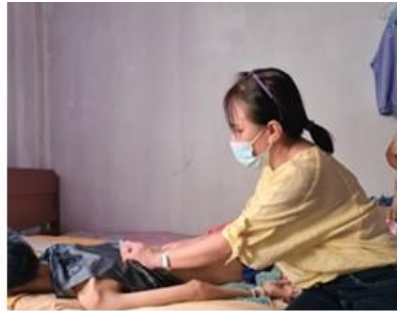Big Size and High Swelling  
Hard skin



Jun.23'21



Smaller size and height drop  
Swelling decreased  
Soft skin







**Thank you**

**Dr. Chintana Bounthalusay**